

# Embolization of a Large Uterine Fibroid

BY ANTONIO RAMPOLDI, MD, AND CARMELO MIGLIORISI, MD

## CASE PRESENTATION

A 48-year-old woman presented to our institution with a history of uterine fibroid treated with high-intensity focused ultrasound.

MRI showed three fibroids, including a larger one with intramural measurements of 46 X 50 X 43 mm (Figure 1). Because of some anatomic complications from the last high-intensity focused ultrasound treatment, the patient was a candidate for uterine fibroid embolization.

## PROCEDURE DESCRIPTION

From a right femoral approach, we catheterized the left uterine artery. Angiographic evaluation showed no abnormal patterns (Figure 2). Due to a clear vaginal artery, we chose not to intervene.

The right side evaluation, however, showed an abnormal pattern related to the larger fibroid (Figure 3). We chose a 0.021-inch, 2.4-F Direxion™ Torqueable Microcatheter with the capacity to inject large particles with a good overall flow rate, great control, and navigability. We used one 2-mL syringe of 500-µm Embosphere™ Microspheres to embolize any feeding vessel of the fibroid.

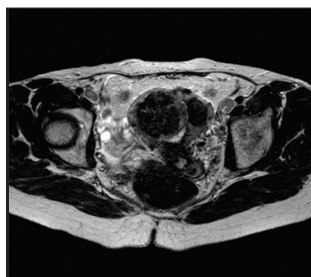


Figure 1.

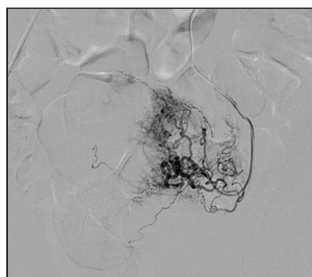


Figure 2.

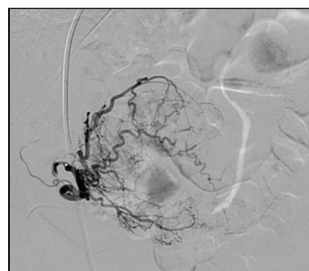


Figure 3.

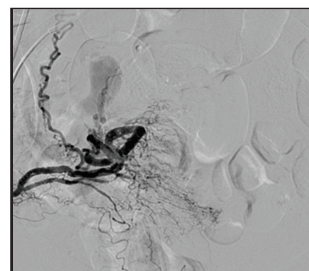


Figure 4.

## FOLLOW-UP AND DISCUSSION

The treatment was successfully performed, and the embolization was completed with good fibroid exclusion. Final angiography confirmed exclusion of the fibroid and preservation of tissue vascularization (Figure 4). ■

### Antonio Rampoldi, MD

Chief of Interventional Radiology  
Niguarda Ca' Granda Hospital  
Milan, Italy

*Disclosures: None.*

### Carmelo Migliorisi, MD

Interventional Radiologist  
Niguarda Ca' Granda Hospital  
Milan, Italy

*Disclosures: None.*